



Research Article

ISSN: 2454-5023
J. Ayu. Herb. Med.
2017; 3(4): 210-215
© 2017, All rights reserved
www.ayurvedjournal.com
Received: 09-09-2017
Accepted: 02-11-2017

Evaluation of potential effects of the aqueous extract of fenugreek seeds on fertility in male rats

Brogi Hind¹, Moumen Zineb¹, Hajji Elbachir¹, EL Amrani Najat², Amsaguine Siham², Radallah Driss²

¹ PhD Student, Laboratory of Biology and Health, Research Unit Associate CNRST - URAC 34, Faculty of Sciences Ben M'Sik, Hassan II-Casablanca University, Casablanca, Morocco

² Professor, Laboratory of Biology and Health, Research Unit Associate CNRST - URAC 34, Faculty of Sciences Ben M'Sik, Hassan II-Casablanca University, Casablanca, Morocco

ABSTRACT

Fenugreek (*Trigonella foenum-graecum* L.) has long been used as a medicinal plant for the treatment of nutritional and metabolic dysfunctions. It has been shown that the daily intake of fenugreek seeds improves feeding behavior in animals. A number of studies have also suggested a link between Fenugreek seeds extracts and fertility but have yielded contradictory results.

In this paper, particular attention has been paid to the impact of consumption of the aqueous extract of fenugreek seeds, prepared according to the traditional Moroccan method, on the spermatic parameters and the pathophysiology of the reproductive system of Wistar rats receiving 450 and 900 mg / kg /day, respectively.

Our study results show the benefits of fenugreekseeds aqueous extract, used in the traditional Moroccan pharmacopoeia on appetite stimulation and weight gain without any significant impact on the fertility and the reproductive performances. Both quantitative and qualitative analysis of sperm parameters (morphology, mobility and vitality) showed no significant variation compared to the controls. In addition, histological examination of seminiferous tubules and reproductive accessory glands (prostate and seminal vesicles) in fenugreek treated rats showed a normal tissue architecture without visible lesion.

These data exclude all potential risks from the consumption of aqueous extract of fenugreek seeds on the fertility and reproductive function in male rats. However, taking into account other data from the literature, this regular consumption should be closely monitored in order to allow the organism to fully benefit from a multiple phytotherapeutic virtues of this plant.

Keywords: Fenugreek seeds, Fertility, Reproductive performance, Sperm parameters, Weight gain.

INTRODUCTION

Fenugreek (*Trigonella foenum-graecum* L.) has been used for a long time in Arab countries. In the Maghreb, it is used for the treatment of wounds, diarrhea, acne, dehydration, anemia, bronchitis, rheumatism, stomach pain, high blood pressure, constipation, either as decoctions or seeds flour blended with honey. It is also known for its ability to *fight* and *prevent hair fall*. This plant is also consumed as a fortifier by women after childbirth. Seeds have important nutritional properties and cholesterol-lowering effects, which are traditionally used as an appetite stimulant and for a weight gain.

However, other data from the literature report potential risks of fenugreek seeds on fertility and reproductive function. In particular, a sterilizing action was observed on the albino rat and the rabbit, whose weight testis decreased with spermatogenesis and histological alterations in the seminiferous tubules [1, 2].

MATERIALS AND METHODS

Animals

In this study, 24 male *Wistar* rats were individually housed in plastic cages in an environment maintained at 21°C ± 1°C, 55 ± 10 % humidity and 12/12 h cycle of light and darkness with access to food enriched with barley and maizand drinking water *ad libitum*.

The animals were randomly assigned into three groups. Each group were composed of 8 male rats. The first subgroup used as a control received drinking water, while the second and third batches were treated with a daily oral administration with aqueous extracted of fenugreek with doses of respectively, 450 and 900 mg/kg/day. All rats (controls and treatments) are regularly checked and weighed every 2 days.

*Corresponding author:
Radallah Driss

Professor, Laboratory of Biology and Health, Research Unit Associate CNRST - URAC 34, Faculty of Sciences Ben M'Sik, Hassan II-Casablanca University, Casablanca, Morocco
Email: driss.radallah[at]Gmail.com

Preparation of aqueous extracts

Trigonella seeds were collected in the Chaouia-Ouardigha region of Morocco. The fenugreek aqueous extract was prepared in the traditional way with a decoction process. The fenugreek seeds soaked in drinking water and allowed to heat for 5 minutes. Then, recovering the aqueous extract by filtration. The extract was conserved at 4°C until required for use. Decoction, a very simple method compared to other methods used (infusion and powder), collects most of the active ingredients while minimizing or even nullifying the toxic effect [3].

Body and organ weights

At the end of the treatment period, animals were sacrificed under anaesthesia and several organs of the male reproductive tract (seminal vesicle, prostate, testis, epididymis) were carefully removed and weighed.

Histological study

After macroscopic examination, liver and kidney samples were fixed in a Bouin-Hollande solution for 24 hours, while the brain was immersed in Karnovsky's fixative for 96 hours. Then, organs were dehydrated in successive ethanol baths, embedded into blocks of paraffin wax and cut into 5- μ m sections. The slides were rehydrated in successive ethanol baths and stained with hematoxylin-eosin with a standard procedure. Histological studies were done using LEICA microscope and LAS EZ software.

Sperm analysis

Sperm count

The testis and epididymis excised from the rats were finely minced into 20 ml of 0.9% NaCl containing 5 μ l of triton X-100. The cell count was carried out directly by microscope counting, using a Malassez cell [4] and was expressed in million/ml of the sperm suspension.

Sperm Motility

The epididymis was removed and cut up in 20 ml of Hanks balanced salt solution at 37°C. Sperm suspension was placed on the malassez cell. Epididymal sperm motility was assessed by calculating motile spermatozoa per unit area and was expressed in percent motility [5,6].

Sperm abnormalities

Examination of sperm morphology was based on the microscopic analysis of stained samples through visual observations. Samples were fixed with ethanol 95 ° for 5 min and smears were prepared. The slides were stained with Gentian Violet for 3 min and submitted to analysis at x400 magnification. A total of 200 spermatozoa from each rat were examined and individually scored normal or abnormal, according to the strict sperm morphology criteria. The morphological abnormalities were divided into head, mid-piece and tail defects.

Sperm Vitality test

This was estimated using eosin-nigrosin staining technique. A fraction of each suspension of the sperm samples was mixed with equal volume of eosin-nigrosin stain and air-dried smears were prepared on glass slides for each sample. At least 200 sperm were assessed under the microscope at a x400 magnification for percentage viability. Stained sperm indicated permeability of sperm to dye and membrane damage whereas unstained sperm had healthy membrane which did

not allow the dye to enter into the sperm cells [7]. If sperm head stains red or pink it was considered dead whilst those whose head white was considered alive.

Statistical analysis

All data collected were subjected to analysis of variance (ANOVA) and the mean between group was compared using Tukey's test for multiple comparisons. Statistical significance was considered if ($p < 0.05$).

RESULTS

Development of weight in rats treated with an aqueous extract of fenugreek seeds

The results analysis showed a slightly higher variation in body weight in rats treated with fenugreek, than those of rat control (Figure 1).

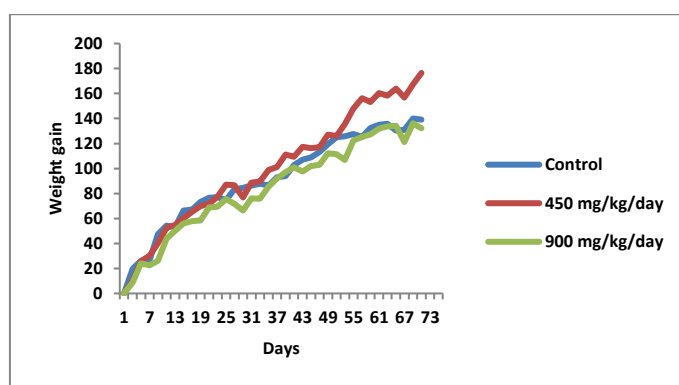


Figure 1: Evolution of weight gain in both groups of rats treated with fenugreek seeds aqueous extract compared to controls.

Impact of treatment with aqueous extract of fenugreek seeds on the relative weight of sexual organs

Our results showed no significant change in the relative weights of reproductive organs in males treated with the aqueous extract of fenugreek seeds (Figure 2).

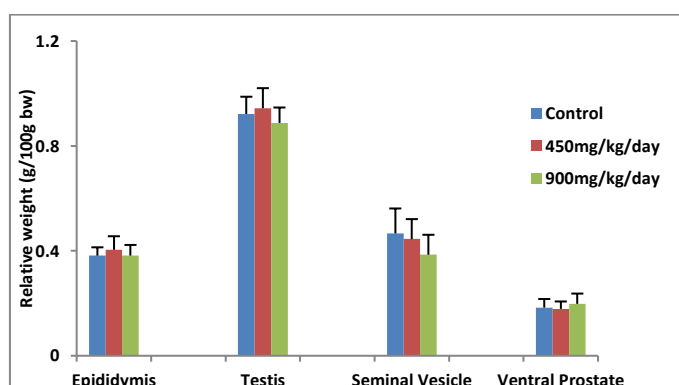


Figure 2: Relative reproductive organ weights in treated and control rats.

Effects of the aqueous extract of fenugreek seeds on sperm parameters in male rats

Sperm count

The results obtained did not reveal any significant change in the number of spermatozoa either in the testis or in the epididymal duct (Figure 3).

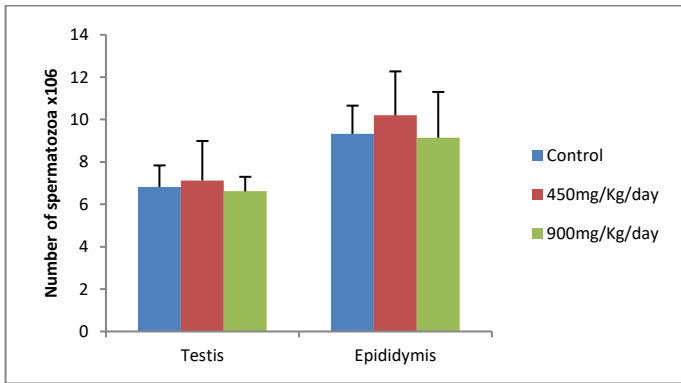


Figure 3: Sperm count in testis and epididymis of rats treated with fenugreek compared to controls.

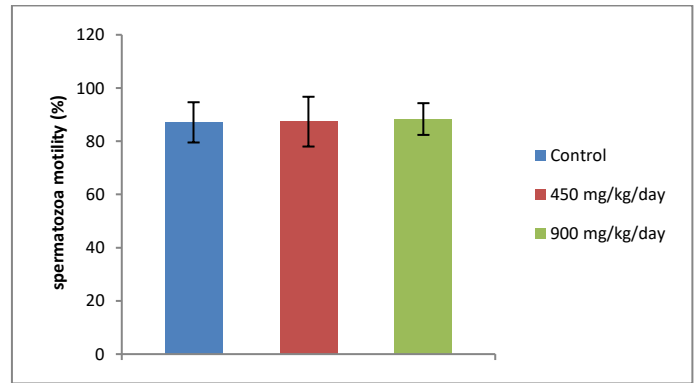


Figure 6: Effects of the aqueous extract of fenugreek seeds on the mobility of spermatozoa after a 75-day treatment.

Sperm vitality

The vitality was evaluated on a smear after staining of cells using eosin-nigrosine. *Live sperm* appear unstained (*white*) and *dead sperm* are stained in *pink* by the eosin (Figure 4).

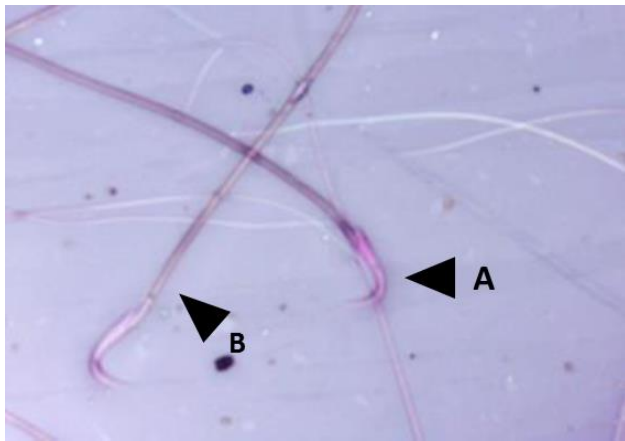


Figure 4: Microscopic examination of sperm after staining with nigrosine and eosin A: Dead sperm, B: Live sperm.

An analysis of the results showed that a treatment of rats with the aqueous extract of fenugreek seeds showed no significant variation in the percentage of dead sperm compared to control rats (Figure 5).

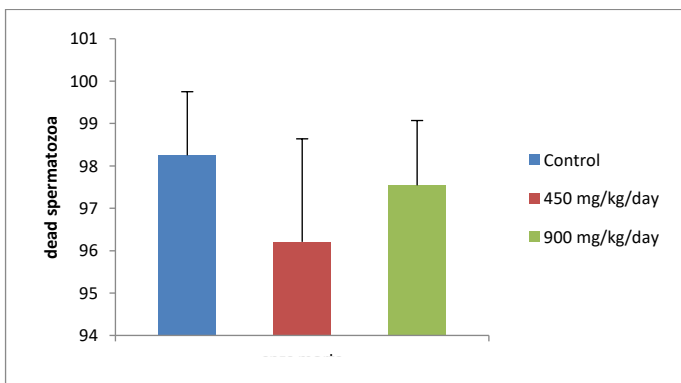


Figure 5: Percentage of dead spermatozoa from fenugreek treated rats compared to control rats.

Sperm mobility

The administration of the aqueous extracts of fenugreek seeds does not affect sperm mobility in treated animals compared to the control group (Figure 6).

Sperm morphology

Analysis of sperm abnormalities showed a very significant decrease ($P < 0.001$) in the percentage of malformed sperm in the fenugreek extract treated animals compared to the control group (Figure 7).

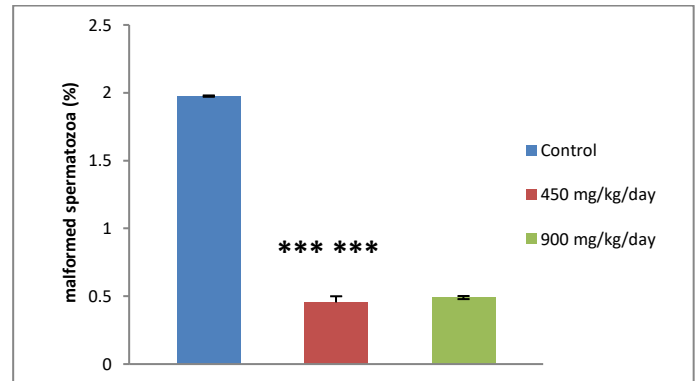


Figure 7: Effects of the aqueous extract of fenugreek seeds on the percentage of malformed spermatozoa.

The abnormalities observed following Gentian violet staining mainly affecting the head, midpiece or tail of spermatozoa (Figure 8).




Figure 8: Optical microscopic examination of some sperm abnormalities stained with gentian violet, A: irregular head (G x 100), B: Macrocephalus (G x 1000), C: Anomaly of intermediate piece (G x 400), D: Coiled flagellum (G x 400).

Histological effects of the fenugreek seeds aqueous extract on accessory reproductive organs

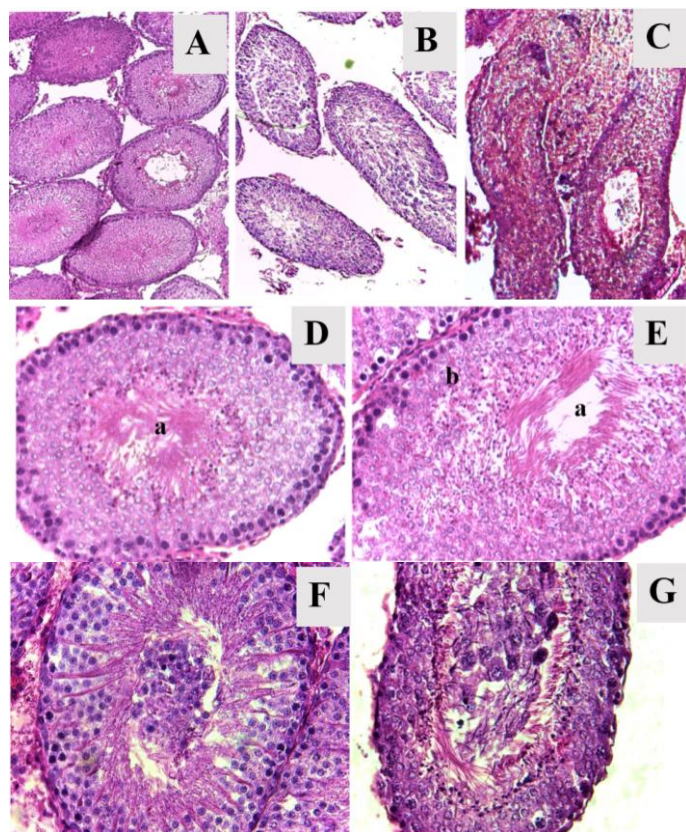
Testicular examination

Morphological examination of the gonads from animals treated with fenugreek seeds aqueous extract revealed no macroscopic visible alteration.

Light microscopy of a control rat testis showed many portions of seminiferous tubules in various planes (Figure 9).

The seminiferous tubules are comprised of the seminiferous epithelium: the somatic Sertoli cells and the developing male germ cells at various stages of development that differentiate into mature spermatozoa. Surrounding the seminiferous epithelium is a layer of basement membrane. Between the tubules is the interstitial space that contains the steroidogenic Leydig cells (Figure 9D).

Meanwhile, histological analysis of testis from rats treated with fenugreek aqueous extract showed a normal tissue architecture and a complete spermatogenesis. Seminiferous tubules were full of spermatozoa in their lumen and sometimes numerous immature germ cells were observed.



a: Lumen, b: seminiferous epithelium, c: sperm.

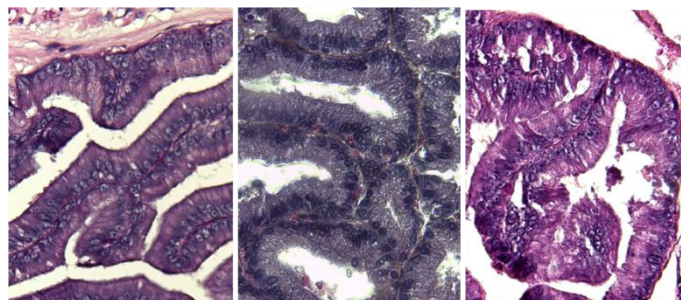
Figure 9: Testis section of rats treated with fenugreek seeds aqueous extract at a dose of 450 mg/kg/j (B et F); or 900 mg/kg/j (C et G) compared to controls (A, D et E)

(A, B et C: G X 100; D, E, F et G: G X 400)

Accessory sex glands examination

The macroscopic and microscopic analysis of the prostate and the seminal vesicle of rats administered with fenugreek aqueous extract revealed no lesions or changes in tissue structures and did not do any damage to the structure (Figures 10). These results seem to show that fenugreek seeds do not disturb the normal operation of these two organs.

Prostate



Seminal vesicles

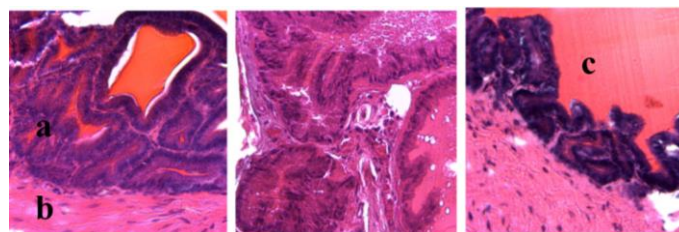


Figure 10: Micrographs of histological sections in the prostates and seminal vesicles of rats treated at different concentrations of the aqueous extract of fenugreek (B and E: 450 mg/kg/day et C and F: 900 mg/kg/day) compared to the control (A and D). a: Glandular epithelium, b: smooth muscle fibers, c: secretion product.

(A, B et C: G X 100; D, E et F: G X 400)

GENERAL DISCUSSION AND CONCLUSION

Fenugreek (*Trigonella foenum-graecum* L.) is a herbaceous plant known for its very important medicinal, therapeutic and nutritional properties. The traditional uses and pharmacological activities of the phytochemicals present in this plant seeds extracts (essential oils, saponins and flavonoids, etc.) are widely documented [8].

The aim of this study is to investigate the effects of the aqueous extract of fenugreek seeds used in the traditional Moroccan pharmacopoeia on body weight changes, relative organ weights and reproductive parameters in male *wistar* rats.

In the first part of our work, we have examined the effect of aqueous extract of fenugreek seeds on body weight in both male and female rats. Thus, we observed in the male rats treated with the aqueous extract, a slightly higher weight change than those of the control. Our results are consistent with the work of Harchane *et al.* (2012) in rats consuming the aqueous extract of fenugreek seeds at a dose of 450 mg/kg/day for 73 days. This weight gain is due to an increase in food intake. Fenugreek stimulates the appetite and acts as a natural anabolic allowing better utilization of dietary intakes [9, 10].

In parallel, a relative weight of reproductive accessory organs (testicles, seminal vesicles and prostate) of male rats treated showed no changes in comparison to controls. Similarly, analysis of quantitative (sperm count) and qualitative (mobility, vitality) sperm parameters in treated animals, revealed no significant variation. At the same time, the incidence of sperm abnormalities in epididymis, which is already very low in normal controls (2%), is reduced to 0.5% in rats treated with aqueous fenugreek extract. Thus, fenugreek would have impact on spermatogenesis and still contribute to fertility and normal testicular function

Moreover, these normal sperm parameters are reinforced by the histological examination of seminiferous tubules in treated rats. It shows a normal seminal epithelium with successive stages of

spermatogenesis. The presence of some seminiferous tubules contained undifferentiated germinal cells does not seem to affect the normal course of spermatogenesis. Between the seminiferous tubules, interstitial tissue rich in blood vessels and Leydig cells, which produce testosterone, was observed.

The reproductive organs of male rats (prostate and seminal vesicles) treated with fenugreek showed no visible macroscopic alteration and normal tissue architecture.

Thus, our results showed clearly that the daily consumption of an aqueous extract of fenugreek seeds, prepared by decoction according to the traditional Moroccan pharmacopoeia, is beneficial on the appetite stimulation and weight gain in male rats with no clear impacts on the fertility and the reproductive performance.

Our data are comparable to those of Mohammed H.A. *et al.* Which showed a normal structure of seminiferous tubules and spermatogenesis in mice treated with an extract obtained by maceration of the fenugreek powder in distilled water. Moreover, this extract would also have a protective effect against androgen excess associated with improvement in spermatogenesis [11]. This repair effect of the tissue architecture of seminiferous tubules attributed to fenugreek seeds has also been reported following histopathological abnormalities induced by chemical compounds such as carbendazim [12] or adriamycin [13].

Our findings disagree with many studies that shows the fenugreek seeds as a potential risk factor in fertility and reproductive function. Kamal and Yadav (1993) reported an antifertility and antiandrogenic activities of a steroid *saponin-rich* fenugreek seed extract in male albino rats. In particular, there has been a reduction in a reproductive organs weight (testis, epididymis, prostate and seminal vesicles) and alteration in histoarchitecture of seminiferous tubules associated with a decrease in epididymal sperm density and mobility. This sterilizing activity in rats could be explained by a decrease in circulating androgen [1]. It has been shown that a cholesterol, a precursor of androgens, decreased with the consumption of fenugreek seeds [9, 10]. For their part, Kassem *et al.* revealed that a feed containing 30% of fenugreek seeds in ad-libitum rabbits results in decreased testicle weight and alterations in the seminiferous tubules structure and interstitial tissue [2].

Similar effects have been noticed with the ethanolic extract of *Trigonella foenum-graecum* seeds. This extract tends to reduce the male fertility by reducing testosterone concentration in the treated rats, and inhibiting both mass and individual motility of the sperms in the treated cocks [14].

Thus, our results compared with previous literature on the impact of fenugreek seeds on the sexual performance of animals revealed contradictory results. These contradictions could be related to the different varieties of fenugreek plant used in various kinds of animal experiments. Moreover, the chemical composition of fenugreek seed would certainly be different and would reflect the difference in environmental factors such as soil type, temperature and rainfall and the time of collection of seeds [15].

Moreover, a various method for extracting a composition of fenugreek seeds bio-active compounds were reported in extant database. Generally, a most commonly-used solvents are ethanol, butanol, methanol or water. Additionally, the aqueous extract used in our study was prepared by decoction, a simple method widely used in traditional Moroccan pharmacopoeia, it allows to collect, unlike other methods (Infusion, powder, seeds), some more active principles while attenuating or even canceling the toxic effect [3].

Recently, it has been shown by our team that prolonged treatment with fenugreek seeds aqueous extract facilitates body weight gain in male and female rats and induces a significant improvement in the lipid profile, particularly for lowering low-density lipoprotein cholesterol (LDL-C) and triglyceride levels [10]. Moreover, we have shown that fenugreek seeds induced a teratogenic effect in pregnant rats [16].

Thus, *Trigonella foenum-graecum* seeds have an impressive range of medicinal uses with high nutritional value. However, its use over a long period of time must be closely monitored and controlled.

Conflict of interest statement

The authors declare that they have no conflict of interest.

REFERENCES

1. Kamal R, Yadav R, et Sharma JD. Efficacy of the steroidal fraction of fenugreek seed extract on fertility of male albino rats. *Phytother* 1993; 7(2):134-138.
2. Kassem A, Al-Aghbari A, AL-Habori M, *et al*-Mamary M. Evaluation of the potential antifertility effect of fenugreek seeds in male and female rabbits. *Contraception* 2006; 73(3):301-306.
3. Salhi S, Fadli M, Zidane L, Douira A. Etudes floristique et ethnobotanique des plantes médicinales de la ville de Kénitra (Maroc). *Lazaroa* 2010; 31:133-143.
4. Farag AT, El-Aswad AF, Shaaban NA. Assessment of reproductive toxicity of orally administered technical dimethoate in male mice. *Reprod. Toxicol* 2007; 23(2):232-238.
5. Blazak WF, Ernst TL, Stewart BE. Potential Indicators of Reproductive Toxicity: Testicular Sperm Production and Epididymal Sperm Number, Transit Time, and Motility in Fischer 344 Rats. *Toxicol. Sci* 1985; 5(6):1097-1103.
6. Lobet JM, Colomina MT, Sirvent JJ, Domingo JL, Corbella J. Reproductive toxicology of aluminum in male mice. *Fundam. Appl. Toxicol. Off. J. Soc. Toxicol* 1995; 25(1):45-51.
7. Farag AT, Eweidah MH, Tayel SM, El-Sebae AH. Developmental toxicity of acephate by gavage in mice. *Reprod. Toxicol. Elmsford* 2000; 14(3):241-245.
8. Rahmani M, Toumi-Benali F, Hamel L, Dif MM. Aperçu ethnobotanique et phytopharmacologique sur *Trigonella foenum-graecum* L. *Phytothérapie* 2015; 1-3.
9. Petit PR, Sauvaire YD, Dominique M, Leconte OM, *et al.* Steroid saponins from fenugreek seeds: Extraction, purification, and pharmacological investigation on feeding behavior and plasma cholesterol. *Steroids* 1995; 60(10):674-680.
10. Harchane H, El Addas H, Amsaguine S, El Amrani N, Radallah D. Effets de l'extrait aqueux des graines du fenugrec (*Trigonella foenum graecum*) sur l'amélioration du profil lipidique et la prise de poids chez le rat. *Phytothérapie* 2012; 10(6):357-362.
11. Mohammed, Qays Kamil DD, Ahmed SA. Effect of fenugreek (*Trigonella foenum-graecum*) seed aqueous extract on testes tissue of anabolic steroid treated adult mice. *Hawler Polytechnic University* 2015; 4(3):035-039.
12. Lamfon H. Effect of fenugreek seed extract on carbendazim-inhibited spermatogenesis in albino rats. *J. Appl. Pharm. Sci.* 2012; 2(4):09-13.
13. Sakr SA, El-shenawy SM, Al-Shabka AM. Aqueous Fenugreek Seed Extract Ameliorates Adriamycin-Induced Cytotoxicity and Testicular Alterations in Albino Rats. *Reprod. Sci.* 2012; 19(1):70-80.
14. Mohammed MM, Mudathir A, Shaddad SAI, Elsharif B, Abu Algasem AAE. Antifertility effects of *Trigonella foenum-graecum* (fenugreek) ethanolic extract in male rats & cocks. *J Pharm Biomed Sci.* 2013; 32(32):1299-1304.

15. Buba F, Ngura U, Abdulrahman AA. Studies on the physicochemical properties of fenugreek (*Trigonella Foenum-Graecum* L.) seeds. *Der Pharmacia Lettre* 2015; 7(3):104-107.
16. Brogi H, Radallah D, El amrani N, Amsaguine S. Evaluation of teratogenic effects of orally administered Fenugreek aqueous extract in pregnant rats. *The Journal of Ethnobiology and Traditional Medicine*. 2016; 126(2016):1210-1218.

HOW TO CITE THIS ARTICLE

Hind B, Zineb M, Elbachir H, Najat ELA, Siham A, Driss R. Evaluation of potential effects of the aqueous extract of fenugreek seeds on fertility in male rats. *Journal of Ayurvedic and Herbal Medicine* 2017; 3(4):210-215.